

Osteochondrodysplasia in Scottish Fold cats

R MALIK^a, GS ALLAN^a, CR HOWLETT^b, DE THOMPSON^c, G JAMES^d, C McWHIRTER^e and K KENDALL^f

Objective To better characterise the bone and joint problems which can develop in Scottish Fold cats.

Design Retrospective study of cases seen in five veterinary clinics and radiographic survey of cats in a cattery.

Results Six Scottish Fold cats (four castrated males, two spayed females) aged between 5 months and 6 years were presented for signs of skeletal disease including lameness, reluctance to jump, a stiff stilted gait, short misshapen distal limbs, swelling of plantar tarsometatarsal regions and short thick inflexible tails. A further four cases (one male, three females, 15 months to 11 years) were identified by radiographic screening of a cattery. A diagnosis of osteochondrodysplasia was based on characteristic radiological findings including irregularity in the size and shape of tarsal, carpal, metatarsal and metacarpal bones, phalanges and caudal vertebrae, narrowed joint spaces, and progressive new bone formation around joints of distal limbs with diffuse osteopenia of adjacent bone. A plantar exostosis caudal to the calcaneus was present in advanced cases. In all nine cases where pedigree information was available, affected cats allegedly originated from the mating of a Scottish Fold to a cat with normal ears. The severity and time of onset of physical signs, and rate of progression and extent of radiographic abnormalities, varied from case to case. Limited histological observations suggested the underlying problem may be an osteochondrodysplasia, related to inadequate cartilage maturation. Clinical signs were ameliorated by administration of pentosan subcutaneously in two of three cats in which it was trialled, and one of these also benefited from an oral glycosaminoglycan preparation.

Conclusions Clinical and radiological findings were ascribed to defective maturation and function of cartilage, particularly in the distal limbs, ears and tail. As all Scottish Fold cats suffered from osteochondrodysplasia of some degree, the best solution would be to avoid using fold-eared cats for breeding and instead use Scottish shorthairs.

Aust Vet J 1999;77:85-92

Key words: Cat, Scottish Fold, osteochondrodysplasia, osteodystrophy, chondrodysplasia, cartilage, autosomal dominant, lameness.

Fold	Scottish Fold
PO	Orally
SFOCD	Scottish Fold osteochondrodysplasia
SC	Subcutaneously

The Scottish Fold is one of the rarest purebred cats in Australia. The defining feature of the breed is its ears, which fold forward (Figure 1). The ear fold is not present at birth but develops at 3 to 4 weeks of age. The breed was developed in Scotland by mating a queen, affected by a natural mutation, to local farm cats and British Shorthairs.¹ Preliminary genetic analyses suggested that the defining genetic abnormality, which causes the auricular cartilage to fold, is inherited as a simple autosomal dominant trait, and the fold-ear allele is designated Fd.^{2,3}

Although fold-eared cats were first bred in 1961 and registered in 1966, there was no mention of any skeletal deformities until 1971 when progressive bony abnormalities and a crippling lameness were recognised.^{1,4} Inheritance studies were based on three different types of matings: skeletally normal Folds to skeletally normal Folds, affected Folds to skeletally normal Folds, and affected Folds to normal cats. Kittens with radiological lesions were only produced from Fold-to-Fold matings.⁵ It was inferred that affected kittens are homozygous for the Fd gene: thus normal cats are fdfd, skeletally normal Scottish Folds are Fdfd, and Scottish Folds with osteodystrophy are FdFd. It has been suggested that breeding of fold-eared cats should be limited, and if used at all, they should be mated only to normal-eared cats.⁵

The breed was banned in England in 1974, but continued to evolve in the USA where initial imports from the UK were outcrossed to numerous other breeds.^{1,4,5} Fold-to-Fold matings were avoided, so only about 50% of offspring had folded ears. Kittens with normal

(prick, pert or upright) ears from this type of mating are known as 'Scottish shorthairs' in North America and Australia (synonym: Scottish Fold S/E [straight ear], Scottish Fold variant; J Sternbeck personal communication).

A limited description of SFOCD was given initially by Jackson,⁵ and more details for a single case were reported recently.⁶ The earliest and most consistent finding is a tail with an abnormally thick and inflexible base. The feet are short, and the underlying skeletal changes result in reduced ability to support weight, an abnormal gait and ultimately lameness. In affected homozygous individuals, joint lesions progress until the cats are unable to walk. Lesions are evident radiographically in kittens aged 7 weeks.⁵ The metaphyses of metatarsal and metacarpal bones are distorted with widened physes, and similar but less marked changes are evident in phalanges. This results in decreased length and abnormal shape of these bones and shortening of distal limbs. The caudal vertebrae are reduced in length, with widened

^aDepartment of Veterinary Clinical Sciences, The University of Sydney, New South Wales 2006

^bSchool of Pathology, The University of New South Wales, Kensington, New South Wales 2052

^cKu-Ring-Gai Veterinary Hospital, 290 Bobbin Head Road, Turramurra North, New South Wales 2074

^dSylvania Veterinary Hospital, 335 Princes Highway, Sylvania Heights, New South Wales 2224

^eChatswood Veterinary Clinic, 80 Sydney Street, Willoughby, New South Wales 2068

^fEast Chatswood Cat Clinic, 346 Penshurst Street, Willoughby, New South Wales 2068

endplates. After age 6 months, gross plantar exostoses of tarsal and metatarsal bones become clinically and radiographically evident. Histologically, tissues from affected kittens show defective bone formation at growth plates, with disordered chondroblast proliferation and irregular groups of cells arranged haphazardly. Physes are grossly expanded with deficient ossification, irregular mineralisation, defective remodelling and supernumerary centres of ossification.

The original observations on SFOCD were published in a journal not widely available outside the UK. Subsequent accounts paraphrase these observations, but consider the problem as a chondrodysplasia.⁷ However, it was noted that problems may occur later in life in some Folds, in which radiographic signs are initially absent,¹ and that heterozygotes may develop skeletal disease that is much milder than observed in homozygous Folds.⁴

This article concerns six cats that developed signs of SFOCD. At least five of them were allegedly the progeny of mating a Fold to a non-Fold. A radiographic survey in a cattery suggested that, contrary to contemporary wisdom, this was likely a widespread problem in this breed.

Case reports

Case 1

A female Fold (Figure 1) brought in for vaccination was considered some-

what small (1.3 kg) for her age (14 weeks). It was presented for evaluation of left hindlimb lameness 5 weeks later, weighing 1.8 kg. Lameness was thought to be worse in the mornings. The distal hindlimbs were abnormally short and misshapen, with excessively curved toenails. Radiographs of the distal extremities and tail at 21 weeks showed changes consistent with SFOCD, including marked malformation of metatarsal and metacarpal bones, phalanges and caudal vertebrae. The proximal tail was thickened and inflexible (Figure 2). No treatment was prescribed and the kitten was spayed. Radiographs at 6 and 11 months showed progression of skeletal abnormalities, with development of periarticular new bone, narrowed joint spaces and apparent loss of bone density in distal limbs. At this time the cat was said to 'seize up' during play. Pentosan polysulphate (3 mg/kg SC every week for 4 weeks) was prescribed. According to the owners, this reduced signs of dysfunction. Current therapy is a complex glycosaminoglycan preparation (Cartiflex, Pharmedica, 2 g PO daily for 30 days, then 2 g twice weekly) that also appears to reduce the cat's discomfort.

Case 2

A 6-month-old castrated Fold was presented for an abnormal gait which had become noticeable over the preceding 3 weeks. The cat's movements had become stiff and stilted, its back had

become arched and bilateral palpable swellings of the tarsi became obvious to the owner. Radiographs demonstrated changes consistent with SFOCD, and the cat was euthanased at its owners' request. Necropsy was not permitted.

Case 3

A 16-month-old male Fold (4.0 kg) was presented for right forelimb lameness of 3 weeks duration. It had been considered normal when vaccinated at 14 weeks (1.8 kg), and castrated 6 weeks later. The affected paw was painful on palpation. Radiographs under general anaesthesia demonstrated changes in the limbs consistent with SFOCD, including malformed metacarpal and metatarsal bones and periarticular new bone formation. The cat was treated with pentosan polysulphate (3 mg/kg SC once weekly for 4 weeks), which produced some reduction in lameness. The cat died after a traffic accident 1 year later and was submitted for necropsy. Tissues were collected for histopathological examination. Inspection at necropsy showed foreshortening of the distal limbs.

Case 4

An 11-month-old male Fold was presented for limping. The cat had been considered normal when vaccinated at 18 weeks and castrated at 8 months. It had been lame for several weeks, and appeared to avoid jumping from any height. Hard, symmetrical, non-painful



Figure 1. The cat in case 1. Note the forward-folding ears.

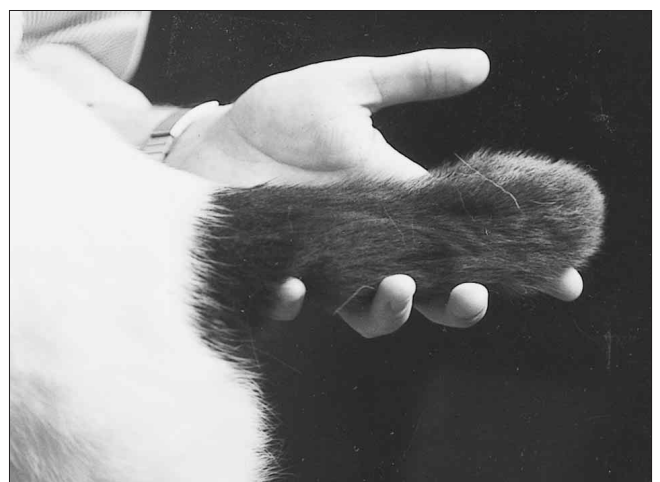

Figure 2. The thickened, shortened, inflexible tail of the cat in case

swellings were palpable around tarsometatarsal regions and similar but less prominent swellings were evident around carpometacarpal regions. Mild bilateral patellar luxation, worse on the left, was present. Hindlimb radiographs demonstrated changes consistent with SFOCD, including abnormalities in shape and size of metatarsal bones, with milder changes in the distal forelimbs. Samples of synovial fluid from carpus and tarsus showed no abnormalities.

The cat was re-presented 10 months later because of worsening signs. The owners considered the cat to be in pain, particularly on cold mornings. It could not jump, and movement was difficult even after it had 'warmed up'. Radiography demonstrated progression of skeletal lesions, with periarticular new bone formation resulting in ankylosis of distal joints. The owners requested euthanasia of the cat. Tissues for histopathological examination were collected at necropsy.

Case 5

A 1-year-old spayed Fold was presented for right forelimb lameness of a few days duration. During physical examination, pain was detected on palpation of the forelimbs. Radiographs demonstrated changes consistent with SFOCD, with shortening and outward bowing of metacarpals two and five, but little periarticular new bone formation. Similar changes were noted also in the hindlimbs. The tail was unremarkable radiographically.

Case 6

A 6-year-old castrated Fold was presented for investigation of a locomotor problem. The cat had been recently rehoused, and its new owner noted the cat had a stiff, short and somewhat immobile tail, and misshapen and splayed claws. The cat's gait was abnormal, it limped occasionally and flinched and vocalised when picked up. Radiographs showed changes consistent with SFOCD; there was little bony deformity, but periarticular new bone was prominent and had resulted in ankylosis of intertarsal and tarsometatarsal joints. The cat was treated with pentosan polysulphate (3 mg/kg SC once weekly for 4 weeks) without discernible improvement. Signs were unchanged 1 year later. The cat's

hindclaws need regular trimming as they tend to grow abnormally.

Further cases

To further assess the prevalence of SFOCD, distal limbs and tails of 'asymptomatic' breeding stock from a commercial cattery were screened radiographically. Five cats were examined, four Folds (three females of 4, 5 and 11 years; one male of 15 months of age) and a Scottish Shorthair (male, 9 years). All Folds had radiographic changes indicative of SFOCD, ranging from very mild (15-month-old male) to severe (4-year-old female), but no abnormalities were detected in the Scottish Shorthair. The changes observed in the worse affected 4-year-old female Fold were more extensive and severe than those of the 11-year-old female. The tail was affected in all Folds except the 5-year-old female.

Mating data

Pedigrees were obtained for nine Folds with SFOCD: cases 1 to 5 and the four affected Folds in the cattery. All cats

originated from the mating of a Fold to a cat with normal ears, this being a Scottish shorthair in seven instances, and a British Shorthair in one. In six cases the queen was a Fold, while in three cases the tom was a Fold. Thus none resulted from a Fold-to-Fold mating. Several of the cats were closely related: cats in cases 2 and 3 and one of the cats from the cattery had the same parents, while cats in cases 4 and 5 and another cat from the cattery were the product of another parent set. Of the remaining three cats, two came from entirely different lines.

Radiographic findings

Radiographs provided the basis for confirming a diagnosis of SFOCD. Changes were similar in all cats, and the two cats subjected to serial radiography showed progressive disease. The rate of progression differed between cats, as did the age of apparent onset of clinical signs. Arbitrarily, we divided the radiographic changes into two components.

Firstly, there were skeletal deformities which were thought to result from

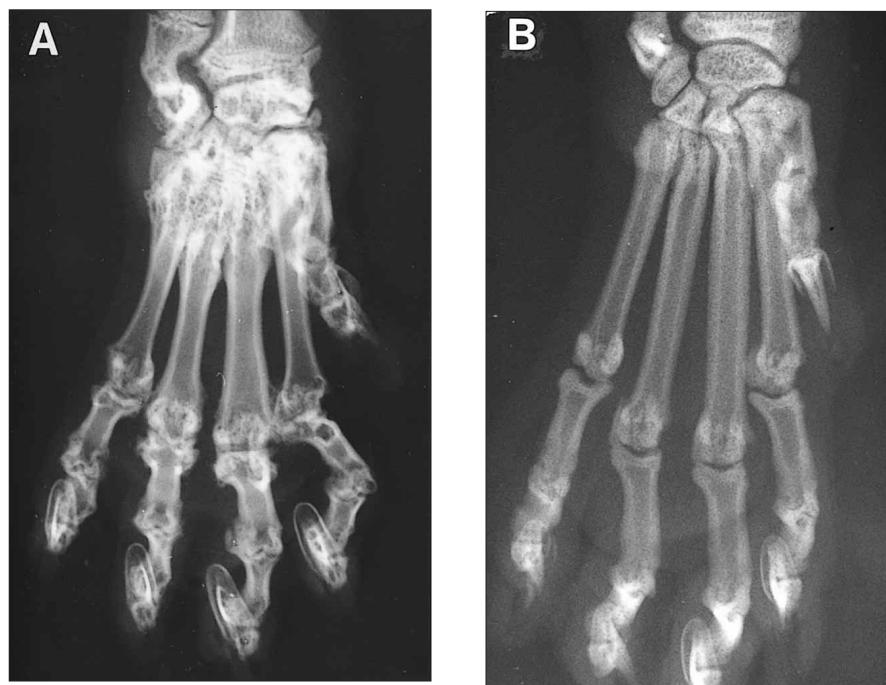


Figure 3. (A) Dorsopalmar radiograph of the distal forelimb of the cat in case 3 at 16 months. The metacarpal bones and phalanges are shortened somewhat, the distal radial and ulnar growth plates are of an abnormal shape, and there is 'mushrooming' of the distal radial metaphysis. There is also extensive periarticular new bone formation around carpal and proximal metacarpal bones that has resulted in bony ankylosis. Intercarpal and carpometacarpal joint spaces appear almost completely obliterated. A dorsopalmar radiograph of a normal cat's metacarpals is provided in (B) for comparison; note the difference in the length of the metacarpal bones and phalanges.

abnormal bone growth during development, and corresponded to the anatomical finding of shortened distal extremities. These changes were conspicuous in cases 1, 3 and 4, although similar but more subtle changes could be discerned in all other cases. In case 3, for example, the metacarpal bones were shorter than normal, of abnormal shape (proximal and distal ends disproportionately large) and of inconsistent length (metacarpals three and four disproportionately shorter) (Figure 3A). Similarly, the phalanges were of abnormal size and shape. Deformities of the distal appendicular skeleton were even more prominent in case 1: all metatarsal and metacarpal bones were shortened and malformed, some having a bent shape with swollen proximal and distal ends, while phalanges were similarly affected (Figures 4 and 5). Radiographs of the tail were not performed routinely, but cats with a short thick tail invariably had caudal vertebrae that were shorter and wider than normal (Figure 6). Interestingly, the tail was unaffected in case 4 and one of the cattery cats despite severe progressive appendicular disease.

Secondly, there were additional bone changes evident in sequential radiographs that suggested a progressive ankylosing polyarthropathy affecting distal limb joints. Changes of this type were present in all cases, but developed more rapidly in cats with distal limb shortening (Figures 3 and 7) than in cases with normally proportioned limbs (Figure 8). Pelvic limbs tended to be earlier and more affected. Periarticular new bone formation, the most conspicuous change, was typically first detected along proximal metatarsals, where it extended and merged with new bone formed on the distal tarsal bones (Figures 7 and 8). These changes were progressive, occurred circumferentially around the tarsometatarsal joint, and eventually resulted in tarsometatarsal and intertarsal ankylosis (Figures 7 and 8). The periarticular new bone was typically smooth, although the extensive new bone that formed plantar to the calcaneus and eventually extended into adjacent soft tissues as an exostoses was more irregular. Intertarsal and tarsometatarsal joint spaces became irregular, indistinct and progressively narrowed, and the corresponding joints in the forelimbs eventually became simi-

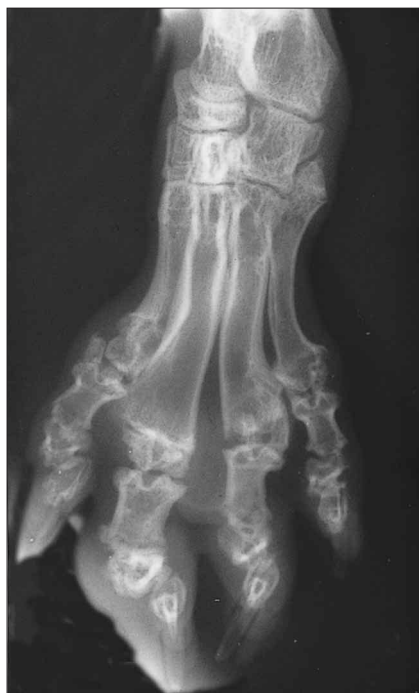

Figure 4. Dorsopalmar radiograph of the distal hindlimb of the cat in case 1 at 6 months. The metatarsal bones are shorter than normal, misshapen asymmetrically, with swelling of the proximal and distal ends and bending of shafts. Intertarsal and tarsometatarsal joint spaces seem normal, and periarticular new bone formation is not apparent.

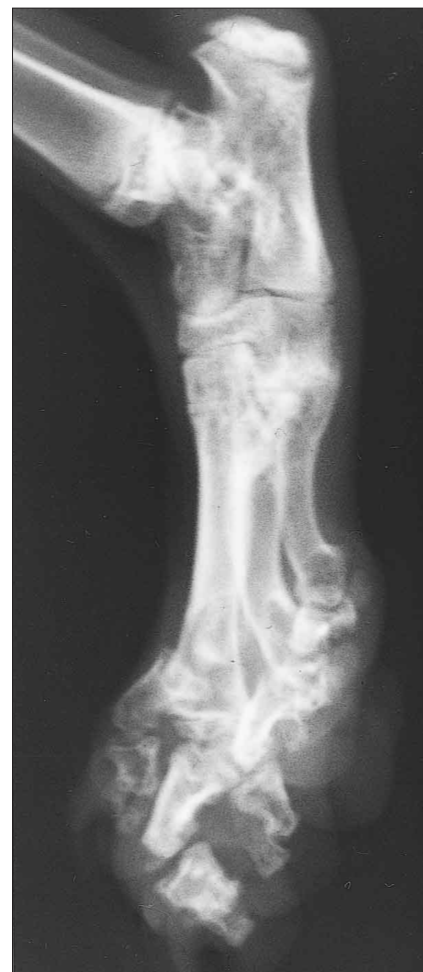

Figure 5. Lateral radiograph of the distal hindlimb of the cat in case 1 at 6 months. The metatarsal bones are shorter than normal, asymmetrically misshapen, with enlargement of proximal and distal ends and bending of shafts. Intertarsal and tarsometatarsal joint spaces are of relatively normal appearance, and periarticular new bone formation is not apparent.

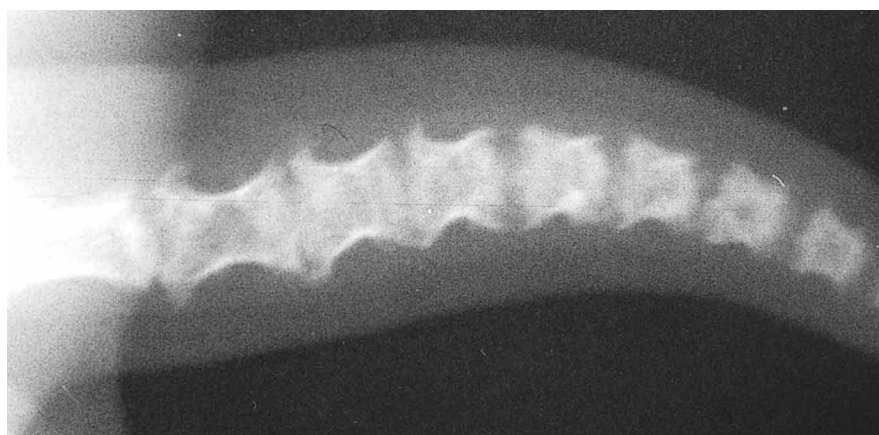


Figure 6. Radiograph of the thickened shortened inflexible tail of the cat in case 1 at 11 months. Several caudal vertebrae are shorter than normal, with enlarged bony vertebral endplates, reduced intervertebral spaces and new bone formation tending towards ankylosis of adjacent vertebrae.

larly affected (Figure 3). As well, tarsal and metatarsal bones became less radio-dense, with irregular punctate areas of osteolucency giving the tarsal bones a moth-eaten appearance (Figure 7).

The proximal limb joints, long bones of the limbs and the vertebral column, except for the tail, appeared unaffected.

Histopathological findings

Tissues from cases 3 and 4 were fixed for 2 to 3 months in buffered formalin (pH 7.2) and decalcified using a rapid decalcification procedure for 2 days followed by a further 5 days in 5% formic acid. The tissues were then routinely dehydrated and embedded in paraffin. Sections cut at 4 and 7 μ m were stained with haematoxylin and eosin. Similar histological changes were observed at the articular surfaces of the phalanges, metatarsal and metacarpal bones. Some interphalangeal joints sectioned were distorted and subluxated. Some bones in the distal limbs had abnormal articular cartilage. The hyaline cartilage was thicker in places: here necrotic cartilaginous foci were evident although the cartilage maintained its microscopic structure, but with chondrocytes failing to take up stain. Nearby cells stained correctly and, on the edge of this thicker articular cartilage, proliferating chondrocytes appeared to grow from the margins towards the centre of the articular cartilage (Figure 9). Where articular cartilage was thicker it appeared to be inadequately resorbed, and the underlying junction between cartilage and bone had a transitional zone with either a discontinuous tide mark or a 'stuttered' layered tide mark. Large isolated islands of hyaline cartilage were observed in some places, extending from the articular cartilage into epiphyseal bone (Figures 10 and 11), and in other places microscopic foci of apparently viable cartilage were enclosed in subchondral bone. These findings suggested that remodelling of cartilage was slowed, perhaps due to delayed or inadequate maturation. Some bones displayed subarticular osseous erosions consisting of areas of osteoclasts, margined by subperiosteal bone formation.

Flaking and fibrillation of the articular cartilage was sometimes evident. Chronic synovitis accompanied these

changes, typically with a small number of fibrous synovial villi and a minimal cellular response. The predominant proliferative cell in the villus was the synovial membrane cell, although occasionally mononuclear cells were present also. The fibrocartilage at tendo-osseous junctions appeared distorted without an ordered junctional array. Mature bone in nodules and spicules was evident in peri-articular dense connective tissue of ligaments and joint capsules, forming osseous projections (enthesophytes). This bone appeared to be forming as a result of an intermembranous process.

In case 3 the distal radial and ulnar growth plates were present but functionally closed. Growth plate cartilage chondrocytes were small, eosinophilic, but somewhat clustered, and each separated by considerable matrix. The chondrocytic morphological features of the physis were more like that of the resting/proliferating chondrocytic zone and these cells seemed not to have entered the hypertrophic stage of maturation. Remodelling of cartilage appeared disturbed as a result of inadequate chondrocytic maturation.

Discussion

The defining phenotypic feature which identifies a cat as a Scottish Fold suggests a developmental cartilage defect, the most obvious manifestation of which is forward folding of the ears. This presumably results from the cartilage of the pinna lacking sufficient resilience to support the ear against the effect of gravity. It is hardly surprising then that some cats with this genetic defect have other abnormalities referable to defective cartilage function.

In order to fully describe the osteochondrodysplasia encountered in Scottish Folds it would be necessary to observe and sample representative tissues during skeletal development, to more closely follow the process of endochondral ossification in distal extremities radiographically and microscopically. Though our histological observations are limited, it seems that the cartilage in bones of distal limbs is replaced slowly, possibly reflecting inappropriate chondrocytic maturation. The presence of large islands of epiphyseal cartilage attached to articular cartilage suggests defective endochondral osteogenesis. The junctions between cartilage and

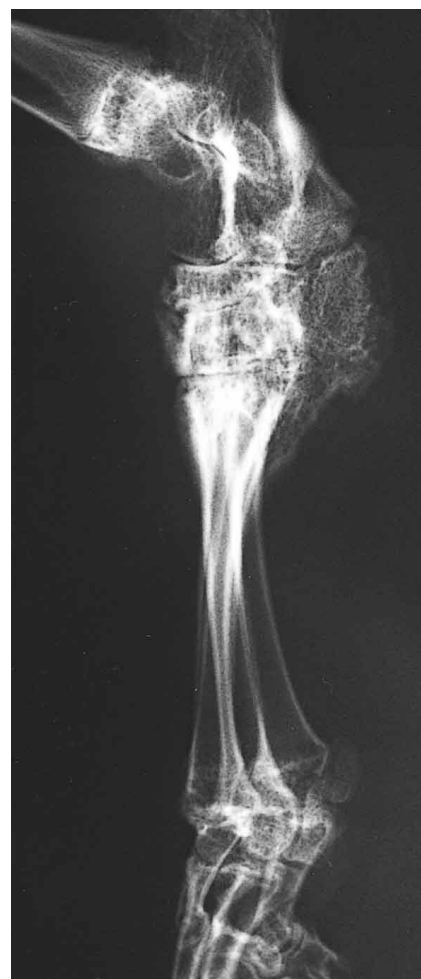

Figure 7. Lateral radiograph of the distal hindlimb of the cat in case 2 at 6 months. The distal tibia and fibula, tarsal and metatarsal bones and phalanges are not markedly deformed, although the metatarsal bones are shorter than normal, with metatarsal bones 2 and 5 being splayed outward. Smooth new bone formation is evident around the tarsus and proximal portion of the metatarsus and has resulted in bony ankylosis of the tarsometatarsal and intertarsal joints. The intertarsal and tarsometatarsal joint spaces appear indistinct and may be narrowed irregularly, and tarsal bones have a moth-eaten appearance, perhaps contributed to by overlying periarticular bone.

bone in these regions have a transition from chondrocytes to osteocytes and this morphological appearance is encountered in conditions such as avian dyschondroplasia⁸ and dyschondroplastic lesions seen in fast-growing large and giant breeds of dogs.⁹ If similar changes occur in physal cartilages during development, there would be

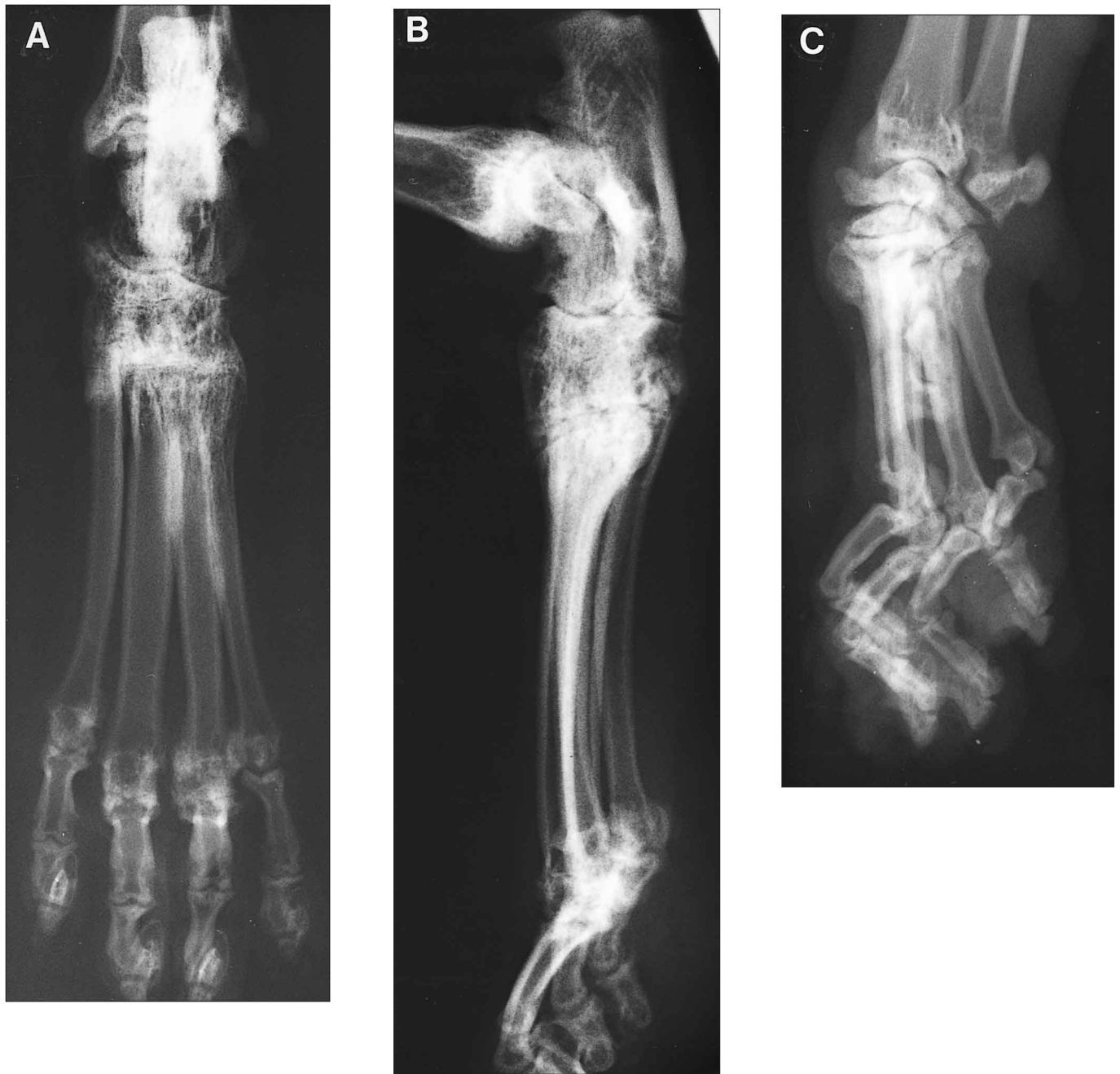

Figure 8. Dorsopalmar (A) and lateral (B) radiographs of the distal pelvic limb of the cat in case 6 at the age of 6 years. Smooth periarticular new bone formation is evident around the tarsus and proximal portion of the metatarsus and has resulted in bony ankylosis of the tarsometatarsal and intertarsal joints. A large enthesophyte is present on the calcaneus, although this is hard to discern in the photograph. The intertarsal and tarsometatarsal joint spaces are indistinct and narrowed. Note that the metatarsal bones are nearly 'normal' in length. Similar changes are evident in the lateral radiograph (C) of the distal thoracic limb.

delayed and dysplastic osteogenesis in certain bones, such as metacarpal and metatarsal bones, which would result in malformation. Thus the abnormalities in size and shape of bones in cats with SFOCD might occur because of defective endochondral ossification in distal extremities.

Later in life, malformation and resulting abnormal mechanical forces presumably take their toll, resulting in subarticular osteoclastosis and periarticular

new bone formation at insertions of tendons and joint capsules, as well as degenerative joint disease and synovitis. Deficiencies in the function of articular cartilage, which normally provides a frictionless intra-articular surface, may contribute to premature and accelerated degenerative joint disease. The severe periarticular new bone formation at distal extremities of affected cats corresponds to new bone formed in the tendons and joint capsules of distal

joints; this may reflect abnormal stresses about affected joints and/or be a more direct result of the abnormal fibrocartilage architecture observed in these regions. Less severely affected cats have little developmental bone malformation and tend to present at an older age, when periarticular new bone formation and allied changes have moved towards ankylosis of distal joints.

The danger of producing cats homozygous for the Fd gene from Fold-

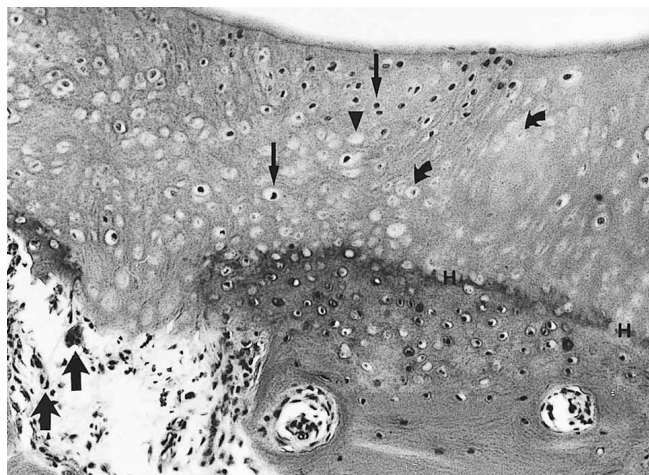


Figure 9. Photomicrograph of articular cartilage from a tarsal bone from the cat in case 3. There is variability in the staining of the chondrocytes at the centre of the articular cartilage: some (small arrows) stain conspicuously with haematoxylin, whereas others (curved arrows) stain faintly suggesting karyolysis, while some chondrocytic lacunae appear empty (arrowhead). The osteochondral junction is represented by a dense haematoxylin line (H). The subchondral bone is absent in one area, resorbed by osteoclasts (large arrows) and replaced by mononuclear mesenchymal cells. Haematoxylin and eosin x 75.

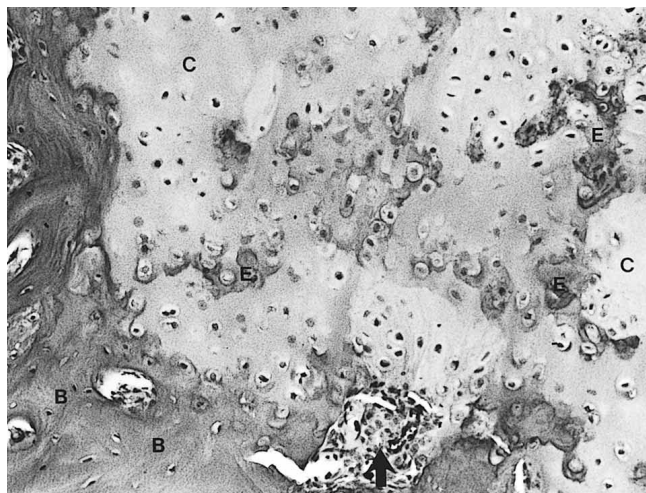


Figure 11. A higher power photomicrograph of the section in Figure 10 displaying an irregular chondro-osseous junction. The cartilaginous matrix (C) has different staining characteristics with eosinophilic foci (E) having similarities to that of nearby osseous matrix (B). An erosion site at the bone-cartilage junction is filled by plump mesenchymal cells (arrow). Haematoxylin and eosin x 75.

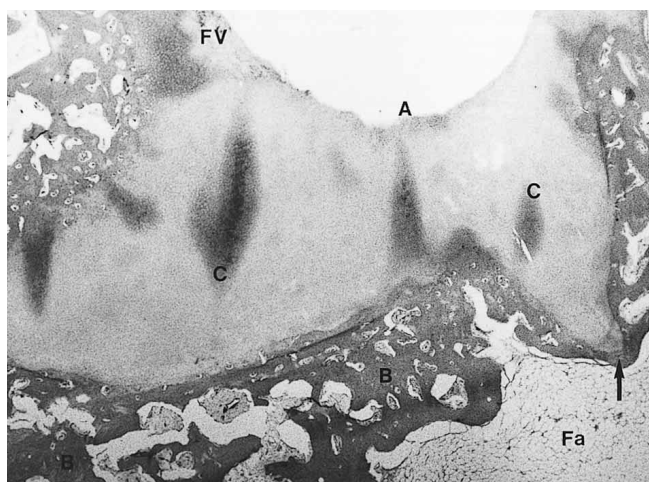


Figure 10. The section displays an irregular mass of cartilage (C) extending from the articular surface (A) of the tarsal bone into the bone (B) and, although a rim of bone separates cartilage from the large central intra-osseous fatty marrow tissue (Fa), this bone is thin in one region (arrow). Part of the joint surface is lined by fibrovascular tissue (FV). Haematoxylin and eosin x 7.5.

to-Fold matings has been long understood by breeders who recognise that severe signs develop early in cats of the FdFd genotype. What is unclear, however, is the extent to which similar but milder changes develop in heterozygous Folds. This report suggests that significant disease can develop in heterozygous Folds as young as 6 months, and similar conclusions were recently made in a case report from California.⁶

Clearly there is considerable variation in the severity of changes and rate of progression, as the cat in case 6 had relatively mild disease at 6 years, whereas cats in cases 2 and 4 were sufficiently affected for owners to opt for euthanasia at ages 6 and 21 months.

We suspect subclinical or mild involvement may be present in nearly all mature heterozygous Folds. The natural course of this disease in affected individuals needs to be established. Such studies could be performed readily, because radiological examination of the distal limbs should provide a sensitive and specific screening tool for cats in which physical signs, such as lameness, a short immobile tail, and plantar tarsal exostoses, are absent. Further information concerning the changes in the bones and joints could be obtained non-invasively using serial computed tomography or magnetic resonance imaging of affected distal extremities.

It could be argued that some of the cats described here originated from matings other than those recorded on their registration papers, but the possibility that this was the case for all nine cats for which pedigrees were available seems remote. Analysis of microsatellites to determine paternity would theoretically be able to confirm or refute this possibility,^{10,11} but was not attempted. Alternatively, Scottish shorthairs used in the matings may have been phenotypically 'normal' but genotypically heterozygous for the Fd gene, due to incomplete penetration of the trait.¹² This possibility is compatible with the observation by breeders that some kittens with folded ears grow to have apparently normal ears.¹³ Another possibility is that inheritance of the Fd gene shows the genetic phenomenon of 'anticipation', whereby expression of the defect develops at a progressively earlier age and/or becomes more severe in succeeding generations. Such phenotypic alterations

have been described for several human disorders inherited in an autosomal dominant fashion including myotonic dystrophy,¹⁴ Huntington's disease,¹⁵ autosomal dominant polycystic kidney disease,¹⁶ and spinocerebellar ataxia type 1.¹⁷ In these disorders, progressive amplification of DNA-triplet repeats within or adjacent to the disease gene occur in successive generations, and this instability of DNA is associated with increased disease severity.¹⁷ If heritable unstable DNA was involved in the genetic inheritance of SFOCD, the phenomenon of anticipation would provide an explanation as to why heterozygous Folds seem more likely to develop clinical signs now than in early studies.⁵

Although more work needs to be done, the conclusion from this case series is that if breeders continue to produce cats with cartilage insufficiently strong to support the weight of the ear, some cats will inevitably develop joint and bone problems because of the underlying cartilage defect. Prospective owners should be warned that Folds may develop musculoskeletal dysfunction later on, and perhaps counselled to keep cats exclusively indoors, where wear and tear on joints is likely to be less. Further studies of the cartilage abnormality in affected cats are warranted, as this may provide valuable insights into the structure and function of cartilage in cats and other species. A tantalising possibility is that the cartilage defect may only be evident or important at lower temperatures, which would explain the tendency for bone and cartilage dysfunction to be most evident at the extremities.

The treatment of affected cats is currently unsatisfactory because the disease is relentlessly progressive, and specific therapy is unlikely to be developed until the underlying defect is defined. A recent report emphasised the value of pantarsal arthrodesis as a means

of alleviating tarsal pain in a severely affected cat,⁶ while our findings suggest that treatment with pentosan and glycosaminoglycans can be helpful. Nonsteroidal anti-inflammatory agents considered to be safe for cats, such as carprofen,^{18,19} may also have a place. As Scottish Shorthairs have the same 'wide, round eyes, sweet expression, soft voice, and fondness for affection' as Folds,¹ a suitable solution to SFOCD would be to abandon using fold-eared cats and instead use Scottish Shorthairs, with occasional outcrosses to British Shorthairs and domestic shorthaired cats to maintain hybrid vigour. If this policy was adopted, the problem of SFOCD could be eliminated in one generation.

Acknowledgments

The authors thank Dr Caroline O'Leary for introducing us to the concept of heritable unstable DNA and anticipation. The cooperation of Bajimbi cattery in facilitating these studies was greatly appreciated. Richard Malik is supported by the Valentine Charlton Bequest of the Post Graduate Foundation of Veterinary Science of The University of Sydney.

References

1. Wastlhuber J. History of domestic cats and cat breeds. In: Pratt, editor. *Feline husbandry diseases and management in the multi-cat environment*. American Veterinary Publications, Goleta, 1991:12-14.
2. Todd NB. Folded-ear cats: further observations. *Carn Genet News* 1972;2:64-65.
3. Dyte CE, Turner P. Further data on folded-ear cats. *Carn Genet News* 1973;2:112.
4. Robinson R, Pedersen NC. Normal genetics, genetic disorders, developmental anomalies and breeding programmes. In: Pratt, editor. *Feline husbandry diseases and management in the multi-cat environment*. American Veterinary Publications, Goleta, 1991:75-76.
5. Jackson OF. Congenital bone lesions in cats with folded ears. *Bull Fel Adv Bur* 1975;14:2-4.
6. Mathews KG, Koblik PD, Knoeckel MJ, Pool RR, Fyfe JC. Resolution of lameness associated with Scottish Fold osteodystrophy following bilateral osteotomies and pantarsal arthrodesis: a case report. *J Am Anim Hosp Assoc* 1995;31:280-288.
7. Bennett D. Musculoskeletal system. In: Chandler EA, Gaskell CJ, Gaskell RM, editors. *Feline medicine and therapeutics*. Blackwell, Oxford, 1994:174.
8. Poulos PW, Reiland S, Elwinger K, Olsson S-E. Skeletal lesions in the broiler, with special reference to dyschondroplasia (osteochondrosis). Pathology, frequency, and clinical significance in two strains of birds on high and low energy food. *Acta Radiol* 1978;Suppl 358:229-276.
9. Olsson S-E. Osteochondrosis in the dog. Pathology, radiographic and clinical diagnosis. *Sven Vet Tidn* 1977;29:547-572.
10. Binns MM, Holmes NG, Marti E, Bowen N. Dog parentage testing using canine microsatellites. *J Small Anim Pract* 1995;36:493-497.
11. Fredholm M, Wintero AK. Efficient resolution of parentage in dogs by amplification of microsatellites. *Anim Genet* 1996;27:19-23.
12. Nicholas FW. *Introduction to veterinary genetics*. Oxford University Press, Oxford, 1996:141-142.
13. Maggitti P. *Scottish fold cats*. Barron's educational series, Hauppauge, 1993:11-5,77-82.
14. Howeler CJ, Busch HFM, Geraedts et al. Anticipation in myotonic dystrophy: fact or fiction. *Brain* 1989;112:779-797.
15. Ridley RM, Firth CD, Crow TJ, Conneally PM. Anticipation in Huntington's disease is inherited through the male line but may originate in the female. *J Med Genet* 1991;28:224-231.
16. Fick GM, Johnson AM, Gabow PA. Is there evidence for anticipation in autosomal-dominant polycystic kidney disease? *Kidney Int* 1994;45:1153-1162.
17. Orr HT, Chung M, Banfi S et al. Expansion of an unstable trinucleotide CAG repeat in spinocerebellar ataxia type 1. *Nat Genet* 1993;4:221-226.
18. McKellar QA, May SA, Lees P. Pharmacology and therapeutics of non-steroidal anti-inflammatory drugs in the dog and cat: 2. Individual agents. *J Small Anim Pract* 1991;32:225-235.
19. Taylor PM, Delatour P, Landoni FM et al. Pharmacodynamics and enantioselective pharmacokinetics of carprofen in the cat. *Res Vet Sci* 1996;60:144-161.

(Accepted for publication 1 September 1998)

Addendum

We recently became aware of another cat with SFOCD, diagnosed by Dr Helen Parry in Queensland. The cat was the result of an accidental mating between a Scottish Fold and a Devon Rex, and it was presented for signs referable to plantar exostoses at 2.5 years of age. Characteristic radiographic findings were present.